

Acetabular Cup Placement Accuracy of a Hand-Held Computer Navigation System for Direct Anterior THA

Bryan Emmerson, MD; Denis Nam, MD; Sridhar Durbhakula, MD; William Lutes, DO; Orian Bortz

Introduction

Cup placement in total hip arthroplasty (THA) has conventionally been guided by the Lewinnek Safe Zone. This safe zone dictates that acetabular component placement should lie between 30-50 degrees of abduction and 5-25 degrees anteversion. Although the clinical importance of the Lewinnek safe zone has recently been questioned,⁵ most surgeons continue to target an acetabular component position within this zone as prior results have shown a decreased risk of dislocation with components placed within those parameters.¹

Several studies have reviewed the percentage of acetabular components that are successfully placed in the Lewinnek safe zone^{2, 3, 4} with outliers published to be as high as 42% for conventional posterior THA. THA through a direct anterior approach is understood to have fewer outliers in acetabular component placement due to visibility of the acetabulum and the use of intraoperative fluoroscopy. Despite these benefits, Lewinnek safe zone outliers remain at 27%.⁴

While the Lewinnek safe zone remains the conventional target for cup placement, evolution within orthopedics continues to refine objectives of THA as they relate to patient outcomes and long term implant function and survival.^{5, 6, 9} The Callanan safe zone is one such example where abduction ranges from 30-45 degrees (and anteversion remains targeted between 5-25 degrees) to minimize component wear. Furthermore, the relationship between spinopelvic anatomy and its influence on total hip arthroplasty component stability continues to be explored and is recognized as being of increased importance. Thus, a device that allows accurate acetabular component position may prove increasingly useful in the future as this relationship is better defined. Navigation and robotic tools may be used to improve cup placement; however, they are typically assessed only for their ability to hold surgeons to the Lewinnek safe zone, with little review of their accuracy as a measurement tool.⁷ It is important for these tools to be validated: (1) against the standard benchmark of the Lewinnek Safe Zone; (2) and for accuracy as a

tool to measure acetabular component abduction and anteversion.

This study seeks to explore the accuracy of HipAlign[®], a disposable, hand-held navigation system, in clinical use to guide cup placement for THA using a direct anterior surgical approach. The objectives of this study are to:

- Compare cup placement accuracy to cups measured on standard post-operative x-ray
- Compare cup placement accuracy to equivalent published data for an optical navigation system
- Compare safe zone outliers using HipAlign to published outliers with fluoroscopic-guided THA
- Compare safe zone outliers using HipAlign to published outliers with robot-assisted THA

Materials and Methods

This study collected data from three surgeons at four hospitals. One hundred and four total hip replacements were performed on 103 patients presenting for elective, primary total hip arthroplasty for a diagnosis of osteoarthritis. All THAs were performed through a direct anterior surgical approach and with the use of the HipAlign System (OrthAlign, Aliso Viejo, CA). All surgeons used the direct, anterior approach using fluoroscopy as their standard surgical approach prior to introduction of the HipAlign device into their practice. Age and body mass index were reviewed for all patients enrolled in this investigation.

The technique for use of the HipAlign system is as follows: The system is mounted onto the ipsilateral iliac crest with two 4.0mm pins. A probe is used to register the landmarks of the anterior pelvic plane: ipsilateral ASIS, contralateral ASIS and pubis. These points, in conjunction with a horizontal reference plane, are used to measure cup abduction and anteversion by attaching a sensor onto the cup impactor. Intraoperatively, acetabular abduction and anteversion angles indicated by the HipAlign device after final cup insertion were recorded. As per standard of care, 6-week postoperative anteroposterior pelvis and anteroposterior hip radiographs were obtained and used to measure acetabular component alignment.

Abduction and anteversion angles were measured using a previously validated technique⁸ and compared to the angles measured by direct anterior HipAlign computer navigation recorded intraoperatively. Acetabular component anteversion was measured on AP radiographs centered on the hip to minimize error due to beam dispersion. Patients were excluded if appropriate radiographs were not obtained or if image quality did not allow for appropriate measurements to be completed.

Statistical Analysis: The mean difference between the intraoperative recording for both acetabular abduction and anteversion and the postoperative radiographic measurement was reported. In addition, the percentage of cases with an abduction angle, anteversion angle, and both within the Lewinnek safe zone was reported.

Results

Accuracy as a measurement tool: Ninety seven patients (ninety eight hips) were included in this study. The number of hips analyzed from each surgeon was 40, 34, and 24. Cup angles measured by radiographs were compared to the angles measured by the HipAlign® navigation system. The mean discrepancy in abduction was $2.6^{\circ} \pm 2.8^{\circ}$ and mean discrepancy in anteversion was $5.1^{\circ} \pm 3.2^{\circ}$. These mean discrepancy values were compared to those previously published for optical navigation systems. (It should be noted that this was the singular study found that reviewed navigation measurement accuracy.) Both data sets were assumed to have a normal distribution to determine the percentage of cups whose post operative image measurement would be within 10 degrees of the angle measured by the device. Statistical analysis showed that 100% of cups using HipAlign would be within 10 degrees of the navigated value for abduction and 94% of cups would be within 10 degrees for anteversion vs. 96% for abduction and 88% for anteversion with the optical navigation system (Kumar) (Figure 1).

HipAlign Accuracy within the Lewinnek Safe Zone: Radiographic measurements showed the mean abduction and anteversion angles were $42.1^{\circ} \pm 3.3^{\circ}$ and $19.2^{\circ} \pm 3.9^{\circ}$, respectively, and 95% of cups were within the Lewinnek safe zone (Figure 2).

Domb, et. al reviewed acetabular component placement accuracy for various techniques, including fluoroscopic guided and robotic assisted for a direct anterior total hip arthroplasty. Domb cited that out of 689 cups, 73% were in the safe zone when using fluoroscopy (Figure 3). Figure 3 also includes gray

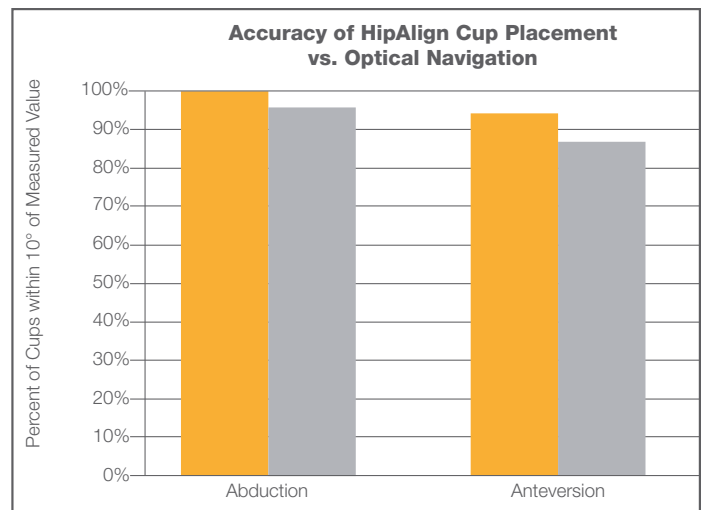


Figure 1 HipAlign (orange) accuracy for cup placement vs. optical navigation (gray). Each system compares to cup angles measured on post-operative images.

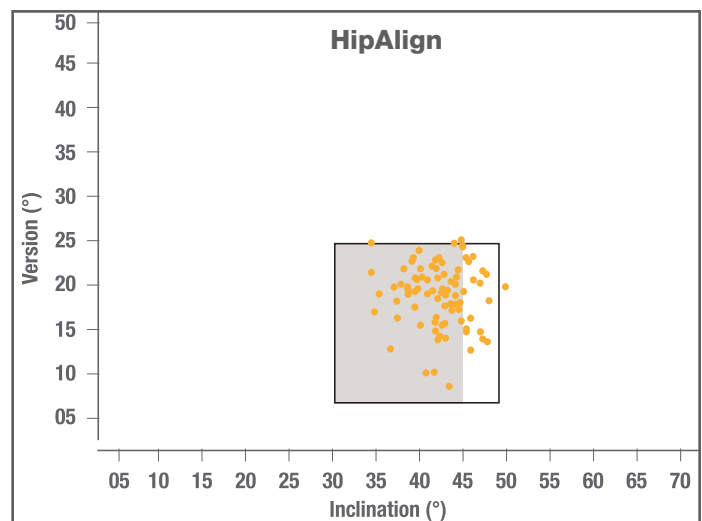


Figure 2 HipAlign-Guided Cup Placement. Black box denotes Lewinnek Safe Zone. Grey shading denotes Callanan safe zone.

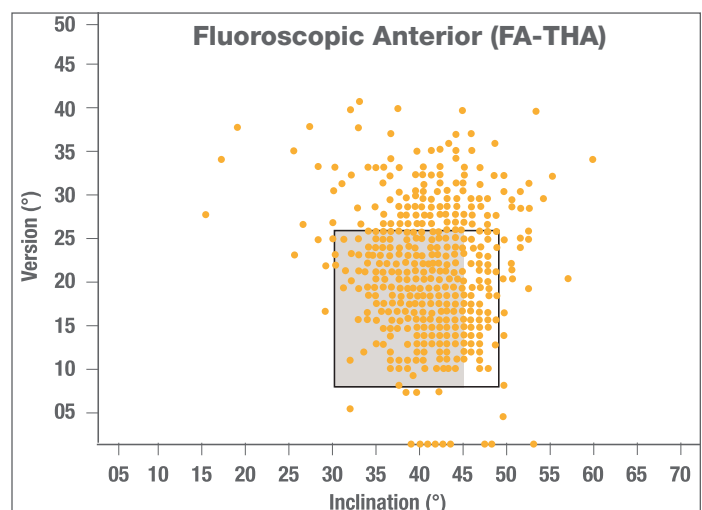


Figure 3 Fluoroscopic-Guided Cup Placement, DA THA (Domb). Black box denotes Lewinnek Safe Zone. Grey shading denotes Callanan safe zone.

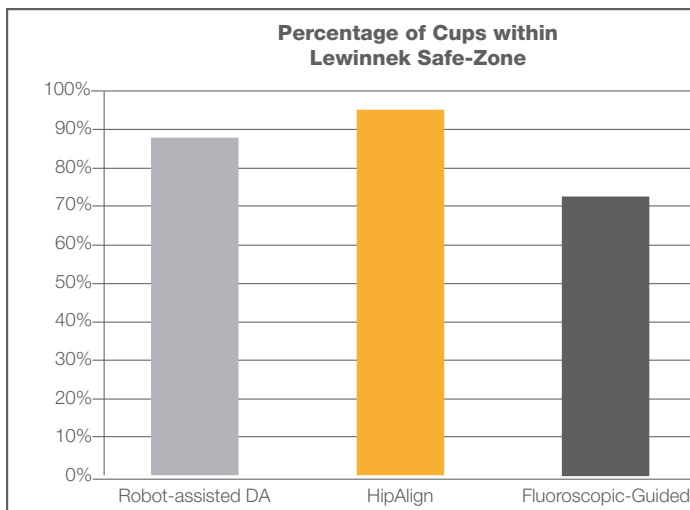


Figure 4 Comparison of Cups within Safe Zone using Fluoroscopy, HipAlign, and Robot-assisted.

shading indicating the Callanan safe zone, where abduction is limited to 45°. Figure 4 includes a comparison of HipAlign to the fluoroscopic guided group as well as the robot-assisted group where 87% of cups were within the safe zone. In order to provide patients with optimal long term clinical outcomes acetabular component position has become critical in assuring minimal liner wear and stability. Acetabular component abduction and anteversion have traditionally been held to the Lewinnek Safe Zone to minimize risk of dislocation.¹ Navigation and robotic tools have been shown to improve acetabular component placement relative to standard technique,⁶ which may, in turn, reduce dislocation as well as its associated complications such as readmission and possible revision.¹¹ Lewinnek’s zone gives a range of $\pm 10^\circ$; however, more narrow safe zones have been suggested to decrease dislocation as well as polyethylene wear.^{6,9} Given the current outlier rates with the Lewinnek zone, tools to improve accuracy of cup angle will become even more important as optimal cup position continues to be refined.

Limitations of this study include inherent challenges of measuring abduction and anteversion on postoperative x-ray. This was mitigated by using a single radiograph reviewer.

This study demonstrates that HipAlign is an accurate tool to guide acetabular component abduction and anteversion. Unlike HipAlign, alternative tools are typically expensive, may require preoperative computerized tomography and traditionally have steep learning curves of 35 cases or more.¹⁰ HipAlign demonstrates improved results while maintaining cost efficiency. The learning curve is minimal for proficiency, adding little operative time and minimal change in surgical technique.

References

- Lewinnek GE, Lewis JL, Tarr R, Compere CL, Zimmerman JR. Dislocations after total hip-replacement arthroplasties. *J Bone Joint Surg Am.* 1978; 60(2):217–220.
- Hassan DM, Johnston GH, Dust WN, Watson G, Dolovich AT. Accuracy of intraoperative assessment of acetabular prosthesis placement. *J Arthroplasty.* 1998; 13(1):80–84.
- Moskal J T, Capps S G. Acetabular component positioning in total hip arthroplasty: an evidence-based analysis. *J Arthroplasty* 2011; 26 (8): 1432–7
- Domb BG, Redmond JM, Louis SS, Alden KJ, Daley RJ, LaReau JM, Petrakos AE, Gui C, Suarez-Ahedo C. Accuracy of Component Positioning in 1980 Total Hip Arthroplasties: A Comparative Analysis by Surgical Technique and Mode of Guidance. *J Arthroplasty.* 2015 Dec;30(12):2208-18.
- Abdel M P, von Roth P, Jennings M T, Hanssen A D, Pagnano M W. What safe zone? The vast majority of dislocated THAs are within the Lewinnek safe zone for acetabular component position. *Clin Orthop Relat Res* 2016; 474 (2): 386–91.
- Danoff J R, Bobman J T, Cunn G, Murtaugh T, Gorroochurn P, Geller J A, Macaulay W. Redefining the acetabular component safe zone for posterior approach total hip arthroplasty. *J Arthroplasty* 2016; 31(2): 506–11.
- Kumar MA, Shetty MS, Kiran KG, Kini AR. Validation of navigation assisted cup placement in total hip arthroplasty. *Int Orthop.* 2012;36(1):17–22.
- Bachhal V, Jindal N, Saini G, Sament R, Kumar V, Chouhan D, Dhillon M. A new method of measuring acetabular cup anteversion on simulated radiographs. *Int Orthop.* 2012;36:1813–1818.
- Callanan M C, Jarrett B, Bragdon C R, Zurakowski D, Rubash H E, Freiberg A A, Malchau H. The John Charnley Award: risk factors for cup malpositioning: quality improvement through a joint registry at a tertiary hospital. *Clin Orthop Relat Res* 2011; 469 (2): 319–29.
- Redmond J.M., Gupta A., Hammarstedt J.E., Petrakos A.E., Finch N.A., Domb B.G. The learning curve associated with robotic-assisted total hip arthroplasty. *Journal of Arthroplasty*, 2015; 30(1): 50-54.
- Sanchez-Sotelo J, Haidukewych GJ, Boberg C.J. Hospital cost of dislocation after primary total hip arthroplasty. *J Bone Joint Surg Am.* 2006 Feb;88(2):290-4.